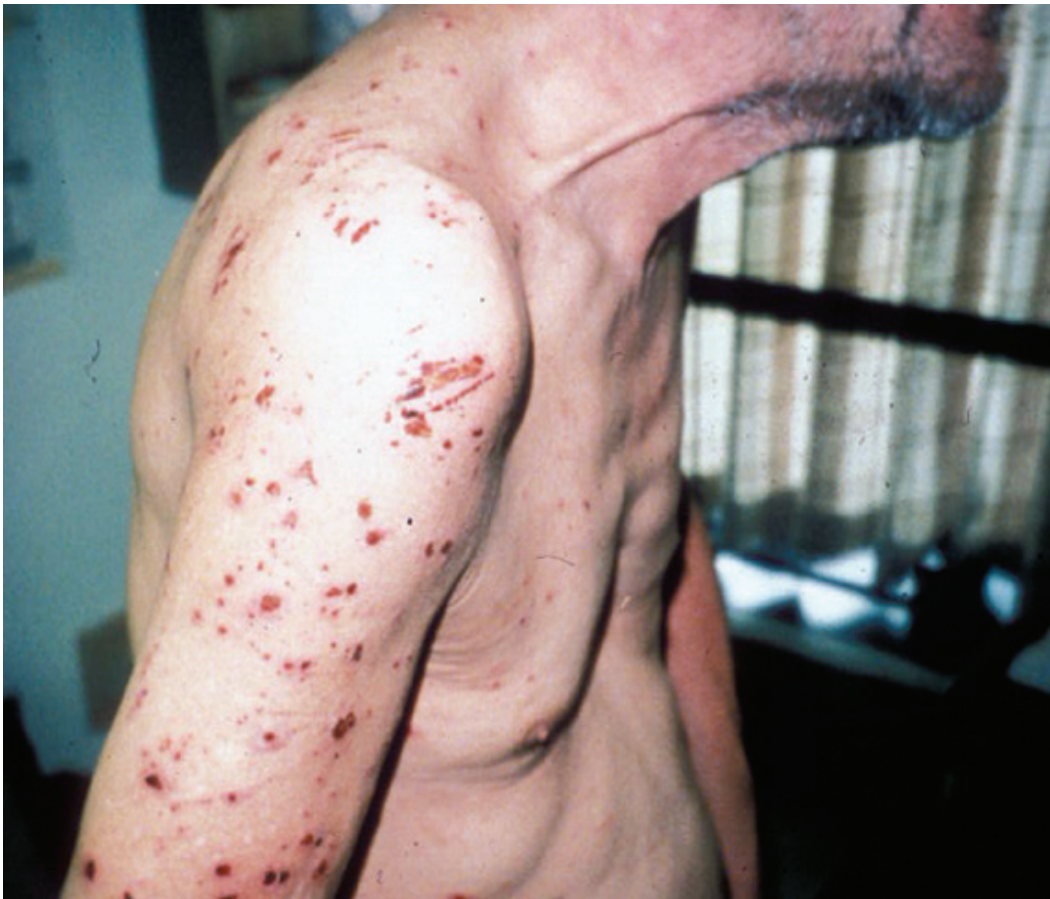



Scabies

Alison May, MD

Scabies is caused by *Sarcoptes scabiei, var. hominus*, the microscopic mite that burrows into a human host to obtain nutrients. Scabies is an extremely contagious infestation that causes an intensely itchy or pruritic rash anywhere on the body, but especially on the trunk, folds of the skin, and on the extremities. Similar to lice, scabies has afflicted humankind for thousands of years and spreads efficiently in crowded living situations such as shelters. Scabies is found worldwide, infesting approximately 300 million people annually and occurring in all climates, socio-economic classes, and races.

Transmission

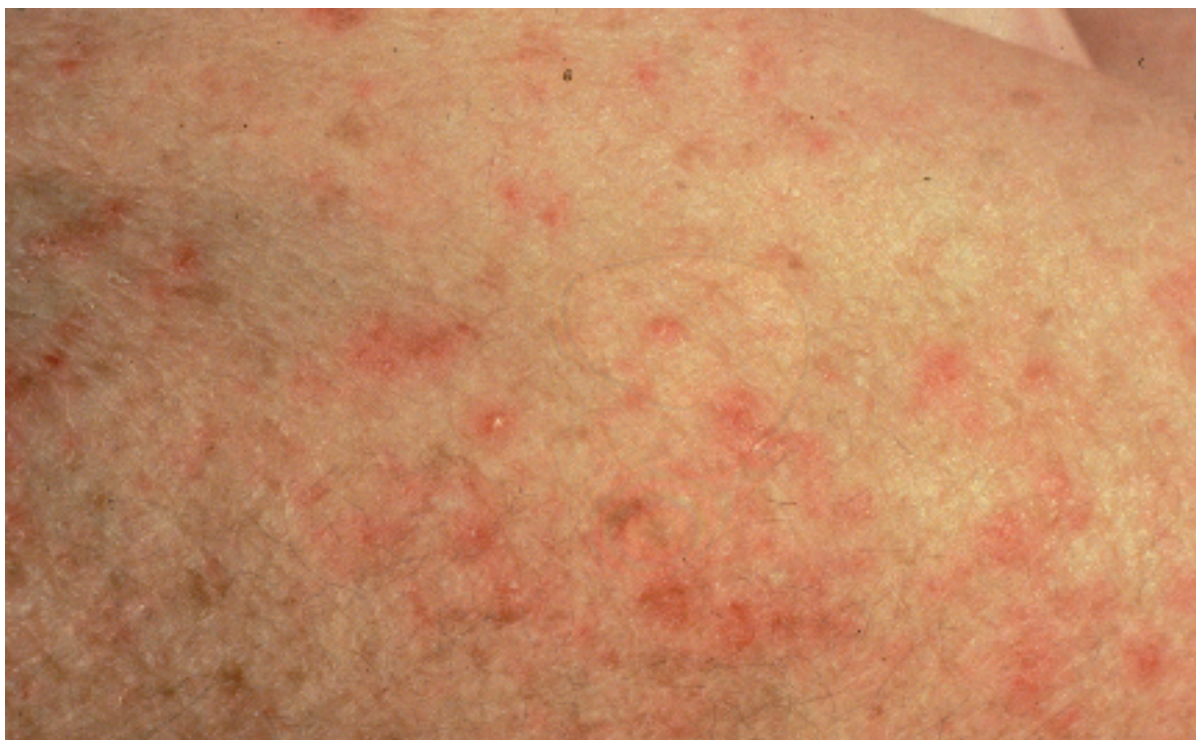Fertilized female mites burrow into human skin to the base of the epidermal stratum corneum. They lay 2-3 eggs a day in these burrows. The eggs hatch as nymphs, which mature in these burrows and return to the skin surface as adults about 2 weeks later. Mating then occurs, and the cycle is repeated as the gravid (pregnant) female mites burrow into the skin of the same or a different host. Full-grown female mites are rounded and about 0.35 mm long with 4 pairs of legs. Scabies is generally transmitted by intimate contact, but transmission also occurs by fomites (often in clothing or bedding).

Symptoms and Diagnosis

The extent of disease is variable and depends on the personal hygiene and immune status of the infected individual, as well as the duration and degree of infestation. More severe disease usually occurs in individuals who are less attentive to personal care or whose sensation is impaired in some way. Scabies cause extreme pruritis, or itchiness, due to the immunologic reaction to the burden of mites, their eggs, and their excreta. Initial infection can remain asymptomatic for up to 6 weeks, whereas reinfection causes an immediate hypersensitivity reaction. Symptoms are generally worse at night or after showering.

Scabies.
This man came to our clinic complaining of a cough and was diagnosed with a triloobar pneumonia. He had an incidental scabies infestation. Note the linear burrows of the mite.
Photo by James O'Connell MD

Scabies Rash.
A popular eruption
of the skin, with faint
linear or wavy ridges
where the mites
have burrowed under
the skin. This rash is
intensely itchy.
Photo by
Irwin Freedberg MD



The dermatological findings of scabies are generally erythematous papules and excoriations, most commonly affecting the interdigital web spaces, wrists, elbows, anterior axillary folds, periumbilical area, buttocks, and the penis. Dark, slightly elevated linear epidermal burrows, generally up to 15 mm long, can also be found, usually in the interdigital web spaces or wrists. A vesicular dot at one end of the burrow can indicate the location of the mite. Scabies can also cause reddish-brown nodules, which are most frequently found in the groin and male genitalia or in the axillae. Less commonly, scabies can present as a more bullous or vesicular eruption. The head, neck, palms, and soles are usually spared, except in infants and young children, in whom these areas are frequently involved.

Norwegian (or crusted) scabies is a severe variant that most commonly occurs in institutionalized, debilitated, or immunosuppressed individuals. The load of parasite is much higher (generally thousands of mites as opposed to 5-10 mites in more classic scabies), and the disease is therefore much more contagious. This variant of the disease has a different appearance, with diffuse crusting of plaques and nodules. The nails can also become thickened with subungual debris. In some patients with Norwegian scabies, the lesions may be more hyperkeratotic and psoriaform, with little or no pruritis, all features which may delay diagnosis.

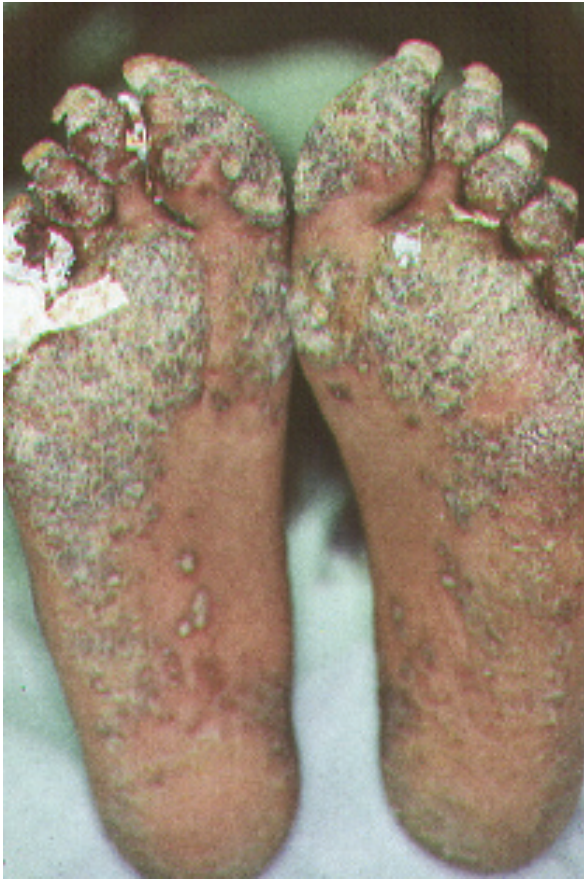Another variant of scabies, *S. scabiei var canis*, causes dog mange and can infest humans who

have contact with the animal. The mite cannot reproduce on the human host, and therefore no burrows are seen in this variant. Treatment of the infested animal results in resolution of the human symptoms as well.

Definitive diagnosis of scabies can be made microscopically by visualization of the mites, eggs, or a fecal pellet. Mineral oil should be dropped onto a burrow or unexcoriated papule, which should then be unroofed by scraping with a sterile #15 scalpel blade. The material obtained should be examined under microscopic low power.

Treatment and Complications

Until recently, topical lindane 1% lotion (Kwell™) was the standard treatment for scabies. Generalized seizures have been reported after repeated applications of lindane, and clinicians must exercise caution when using this medication. The risk seems to be greater in small children (because of their high surface area-to-mass ratio), in people with neurological disease, or when lindane is applied after a warm bath (vasodilation increases absorption). This toxicity, as well as concerns about possible resistance to lindane, have resulted in the use of permethrin 5% cream (Elimite™) as the treatment of choice for scabies. A single application of permethrin is usually sufficient when applied to a clean and dry body after a tepid bath or shower. The entire skin surface should be covered from chin to toes with a thin layer of the agent, including the



area behind the ears, between the fingers and toes, the groin, between the buttocks, and under finger and toenails. The medicine should be left on for 8-10 hours and then washed off. The patient should then put on clean clothes. The treatment may be repeated in 1 week if necessary. Permethrin is safe for children over 2 months of age.

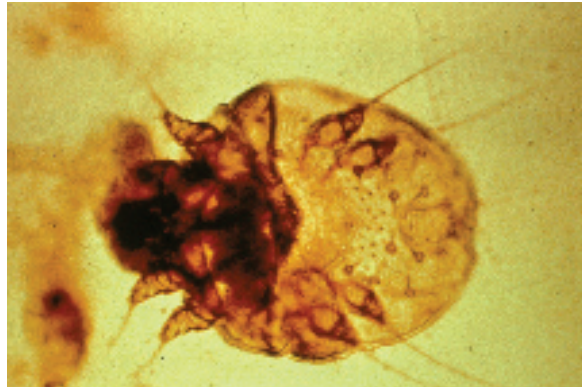
Though less desirable for the reasons already discussed, lindane 1% lotion (Kwell™) may be used and should be applied in the same way as permethrin. Lindane should not be used in pregnant or nursing women or in young children.

Another alternative treatment is 6% precipitated sulfur in petrolatum which is safe in pregnancy, lactation, and for children younger than 2 months old. This medication is applied nightly for 3 consecutive nights and washed off completely 24 hours after the final application. This agent is messy, stains, and has an odor, but it is quite effective.

One oral regimen is available. A single dose of ivermectin 200 mcg/kg (Stromectol™) has been found to be effective in healthy patients as well as in many patients with HIV infection and crusted scabies. Patients with severe disease may require a second or third treatment or may require concomitant treatment with a topical scabicide agent. Experience with ivermectin in the treatment

of scabies is limited, and its use should therefore be considered experimental. Ivermectin should not be used in pregnancy or in children who weigh less than 15 kg.

After treatment is completed, clothing and bed linens used during the 3 days preceding treatment should be discarded or machine washed in hot, soapy water and then dried in the hot setting



of a household dryer. The treatment of intimate contacts is recommended, even when they are asymptomatic.

In Norwegian scabies, topical agents should be applied to the scalp, under the nails, and to the face excluding the areas surrounding the eyes, nose, and mouth. Multiple sequential regimens may be required. In addition, treatment with a keratolytic agent such as 6% salicylic acid may be necessary in order to assure adequate penetration of the scabicide agents. Because of the extremely infectious nature of this variant, isolation of the index case is extremely important, and treatment of the environment as well as of exposed contacts is indicated.

Pruritis may persist for several weeks after treatment for scabies, even though effectively treated patients are no longer infectious after one day. Antihistamines and calamine lotion are effective for relief of these symptoms. Topical steroids or glucocorticoids can be helpful in the relief of pruritis after successful treatment is completed.

In addition to scabicide agents, all patients should trim their fingernails. Permethrin should be reapplied to the hands whenever they are washed during treatment.

Repeated treatment with any scabicide agent may cause an allergic contact dermatitis. Other complications of scabies include secondary eczema or impetigo that are generally caused by *Staphylococcus aureus*. Oral antibiotics may be necessary to treat secondary bacterial infections. Some strains of streptococci have also been found to cause a

(far left)
Norwegian Scabies. This man with HIV/AIDS has his feet with marked hyperkeratosis. Intense nocturnal pruritis is highly characteristic of these often polymorphic lesions. Photo by Jon Fuller MD

(near left)
Sarcoptes scabiei. This mite causes scabies and is seen here under the microscope. Photo by Howard Koh MD

superinfection that can lead to glomerulonephritis.

Prevention and Control

Prevention and control are largely described in the preceding sections. Mites can generally survive for around one day away from the human host, so surfaces that cannot be washed should be vacuumed. Close contacts of patients with scabies should be treated at the same time as the index case.

Summary

Scabies is an intensely pruritic eruption caused by a mite that burrows under the skin. It is highly contagious and is spread by close personal contact or by the sharing of clothing or linens. Scabies can be effectively treated by the application of topical

agents. Prevention of spread of the disease is dependent on the appropriate laundering of clothing and linens, as well as treatment of close contacts of anyone who has scabies. ■■

The author of this chapter gratefully acknowledges the invaluable contribution of Barry Bock, RN, who authored this chapter in the original Manual.

Scabies Medication List		
Generic	Brand Name	Cost
1% lindane lotion	Kwell	\$
permethrin 5% cream	Elimite	\$\$
ivermectin 200 mcg/kg	Stromectol	\$

References

- Maguire J, Spielman A. Ectoparasite infestations, arthropod bites and stings. In: Braunwald E, Fauci AS, Kasper DL, et al., eds. *Harrison's Principles of Internal Medicine*. 15th ed. New York: McGraw-Hill; 2001:2622-2624.
- Meinking TL, Taplin D, Hermida JL, et al. The treatment of scabies with ivermectin. *New England Journal of Medicine* 333(1):26-30.
- Mathison GE. Of mites and men: lessons in scabies for the infectious diseases clinician *Clinical Infectious Disease* 1998;27(3):646-648.
- Orkin M, Maibach HI. Scabies and Pediculosis. In: Wonsiewicz M, Englis MR, Bauer L, eds. *Fitzpatrick's Dermatology in General Medicine*. 5th ed. New York: McGraw-Hill; 1999:2677-2680.